

Testicular biometry, ultrastructure, cellular cytometry and hormonal profile in relation to age in Egyptian buffaloes.

Asmaa Ghania; Sosa, G. A; Mahmoud, A. E., and Agag, M. A.

Faculty of veterinary medicine, Banha University, Department of Theriogenology, Egypt

Animal Production Research Institute, Dokki, Giza1269, Egypt.

Abstract:

This study was conducted on a number of (30) buffaloes in Qalubia. The age ranged from 12 to 36 month. There were divided into two groups: group (I) and group (II), their ages ranged from <18 month and ≥ 18 till 36 month, respectively. Testosterone levels in the blood, testicular biometry by the optical and the electronic microscope, and finally flow cytometry of the testicular cells were estimated. it was concluded that: The testosterone hormone level in the blood in group (I) and in group (II) was 1.9 ± 0.48 and 1.07 ± 0.35 ng/ ml serum prospectively, weight, length and width of the testicle in group (I) was 75 ± 13.8 gm., 7.3 ± 0.48 cm and 4.22 ± 0.31 cm, respectively, and in group (II) was 118.38 ± 11.29 gm., 8.12 ± 0.63 cm, and 5.0 ± 0.23 cm, respectively. The diameter of the seminiferous tubules in group (I) was $99.90 \pm 17.4 \mu\text{m}$, while in group (II) was $104.6 \pm 15.82 \mu\text{m}$. The number of leydig cells in group (I) was 40.14 ± 15.52 , and in group (II) was 49.16 ± 27.99 . The lining epithelium thickness of the seminiferous tubules in group (I) was $26.06 \pm 5.51 \mu\text{m}$, and in group (II) was $27.64 \pm 5.52 \mu\text{m}$, while degree of cell degeneration in group (I) was 6.12 ± 0.79 and in group (II) was 4.62 ± 0.66 . By using flow cytometer there was difference between 2 age group in the testicular cell and apoptosis. An electron micrograph showing difference in the testicular cells ultrastructure.

Keyword: Testis, Buffalo bull, Hormonal profile ,flowcytometry, Electron microscope..

Introduction

In Egypt there are 3. 9 million heads of buffaloes, buffalo production represents about 24.5 % of the agricultural gross domestic products. **(Abdel-Salam and Fahim, 2018)**. Egyptian buffaloes divided into 2 main breeds, Beheri and Saidi, **(Khishin, 1951)**. Biometric parameters as testicular weight, testicular length, and scrotal circumference are essential in the evaluation of breeding **(Brito, et al, 2004)**. During the development of testes from 1 to 24 months in Nili-Ravi buffalo the changes are revealed by **Ahmad, et al. (2010)**. At1 month, sex cords were much smaller than other age groups. At 6 months, the seminiferous tubules were solid, 36. 2 mm in diameter and had few cells, no lumen, and testes weight=17(g). At 12- months spermatogonia cells are noted, tubule diameter increased, centralization, and formation of sertoli cells completed and testes weight=75(g). At 18- months tubule diameter was 165 mm, round and elongated spermatid exited abundantly, Lumen fully formed, and also they revealed that the seminiferous tubule diameter is 200 mm. The mediastinum testis consisted of connective tissue extended through the long axis of the testis it linked to tunica albuginea by radiating rete testis which was constant with the ductile efferent **(Eurell and Frappier, 2013)**. Seminiferous tubules wall consisted of lamina propria, basement membrane, and lined with stratified epithelium that has Sertoli and spermatogenic cells, **(Bashir, et al, 2012)**. Series of mitosis occur to spermatogonia to form primary spermatocyte then it undergoes 2 series of meiosis forming

round spermatid that undergo morphological changes to give elongated spermatid (**Berndtson, et al, 2014**). **Finkelstein, et al, (2013)** stated that testosterone is a male sex hormone that regulates many functions along with sperm production. It circulating in bounded form or in free form, evaluating of it occur by (RIAs), (EIAs) and (LC-MS), (**Mehta and Paduch, 2013**). Testosterone concentrations were lower in young with a range of 0.2 to 0.6 ng /ml. and increased in adult males **Gunarajasingam, et al, (1985)**. During puberty the concentration of androgen increased for the start of spermatogenesis than that required for maintaining adult spermatogenesis (**Handelsman, et al, 1999 and O'Donnell, et al, 2017**). Using of DNA flow cytometer facilitates rapid and accurate quantitation of large number of testicular germ cells population in the animal as a function of sexual maturity and so is considered an effective method for assessing spermatogenesis (**Aravindan, et al, 1990**). So the current work aimed to study the quantitative and qualitative testicular parameters in relation to testosterone profile and puberty in Egyptian buffalo bulls.

Materials and Methods

The present study was carried out on the testes of Egyptian buffalo during the period from January 2018 to October 2019 at Theriogenology department; Faculty of Veterinary Medicine, Benha University, and Animal Reproduction.

Materials:

Testicles:

Testes were collected from apparently healthy slaughtered buffalos aged (12month - 36month) and divided into two groups Group (I) <18 month and Group (II) ≥18 till (36) month immediately after slaughter (**Gofur, et. al, 2008**), at Toukh, Met Nama abattoir, Qalyubia and ELwarak abattoir, Giza. The selected testicles were free from any gross pathological lesions. Small pieces of testes were fixed in the "Bouin's fluid" (**Gridley, 1960**). The age of the animal is determined in the abattoir by dentation, **U.S.department of agriculture, (1898), Parish and Karisch, (2013)**.

Blood samples:

Samples were collected from animals immediately after slaughtering and froze until estimated.

Chemicals for testosterone profile:

Reagent – work solutions: (Thermo Fisher scientific):

Reagent 1	Anti-testosterone -Ab~biotin: Biotinylated monoclonal anti-testosterone antibody (buffalo) 40ng/ml. -Releasing reagent 2-bromoestradiol. -MES buffer 50 mmol /L, PH 6.0
----------------------	---

Reagent 2	Testosterone-peptide~RU (bpy): Testosterone derivative, labeled with ruthenium complex 1.5 ng /ml. -MES buffer 50 mmol /L, PH 6.0 -Preservative.
Micro-particles	Streptavidin-coated microparticles: Streptavidin-coated microparticles 0.72 mg/ ml. - Preservative.

Methods:

Determination of serum Testosterone Concentration (ng /ml) :(Rommerts, 2004),

Total serum testosterone was determined by using the Electrochemiluminescence immunoassay (ECLIA) which intended for use on Elecsys and Cobase immunoassay analyzer.

1-first incubation (9minutes): (to release testosterone) 20 µl of the sample is incubated with a biotinylated monoclonal testosterone specific antibody and 2-bromoestradiol; with the amount of antibody binding sites consequently occupied relying on the testosterone concentration in the sample

2-Second incubation (9minutes): After the adding of the streptavidin-coated microparticles and a derivative of testosterone, labeled with a ruthenium complex, the complex turns out to be bound to the solid phase via interaction of streptavidin and biotin.

3-The reaction combination is aspirated into the measuring cell where the microparticles are magnetically caught onto the surface of the electrode. Boundless substances are then removed with Pro Cell.

4-Application of the voltage to the electrode encourages chemiluminescent release which is measured by a photomultiplier.

5-Results are determined through a calibration curve which is instrument-mainly generated by 2-point calibration and a master curve provided with the reagent barcode.

Flow –cytometer analysis: (vindlov, 1977and Hacker- Klom, et al, 1999).

In a round-bottom tube One ml of testicular sample diluted with phosphate buffer solution was taken and rinsed twice with PBS before its fixation. Directly by using 1ml ice-cold absolute alcohol drop by drop with softly shaking the sample was fixed and preserved at +4 °C till staining. propidium iodide Staining for DNA ploidy was occurred according to the method described by **vindlov, (1977)**. Another sample was stained using sodium dodecidyle sulfate and handled according to **Hacker- Klom, et al, (1999)** for measuring the decondensation. Flow cytometric analysis was pointed to measuring parameters: cellular debris percentage in sub-haploid region (>1ml), haploid round spermatid percentage at1-ml peak mature haploid spermatozoa percentage at 1-ml peak, diploid spermatozoa percentage in 2-ml peak, chromatin decondensation and chromatin condensation percentage were evaluated by using FACS caliber flow cytometer.

Transmission electron microscopy (TEM):

- Immersion fixation of the tissue by using a modified **Karnovsky (1965)**

work solution:

2.5 % buffered glutaraldehyde + 2 % paraformaldehyde in 0.1 M, sodium phosphate buffer pH 7.4

- let tissue overnight at 4° C, wash 3 x 15 minutes in 0.1 M sodium phosphate buffer + 0.1 M Sucrose

- postfix 90 minutes. In 2 % sodium phosphate buffered osmium tetroxide pH7.4

-wash 3 x15minutes in 0.1 Msodium p

-Dehydrate 2x15 minutes: 30% ethanol phosphatebuffer pH7.4

- dehydrate 2 x 15 min: 50 % ethanol (in distilled water)

- 2 x 15 minutes. 80 % ethanol

- 2 x 15 minutes. 90 % ethanol

- 2 x 15 minutes. 96 % ethanol

- 3 x 20 minutes. 100 % ethanol

-or 2x15 minutes in Acetone

- 30 minutes. 2:1 acetone: Epon Combination

- 30 minutes. 2:1 acetone: Epon Combination

- 30 minutes. 1:2 acetones: Epon compination

-Epon pure solution overnight at 4°C

- New fresh Epon solution

- Place in incubator for ~24 hours at 70° C for polymerization

- cut with an ultramicrotome set to 50 - 100 nm section thickness

- wash sections to grids made of Copper

- Post-contrast of sections according to **Reynolds (1963)**

- 10 minutes. 8 % uranyl acetate

- 5 minutes .1 % lead citrate

after the drying for ~15 minutes sections may be examined in a transmission electron microscope, **(Reynolds,1963)** and **(Karnovsky, 1965)**.

Ultrathin sections were examined at 160 kV using a JEOL JEM -2100 at EM Unit, Mansoura University, Egypt.

Statistical analysis:

The Data were statistically analyzed using IBM-SPSS for Windows **(Version 21, statistical software, 2017) and (Ruxton, 2006)**

Results

Morphology of buffalo testes:

General morphological appearance of buffalo bull:

The testes of the buffalo were located in between two thighs in vertical manner, general covered with skin. The tunica albuginea and the mediastinum testes were examined in a cross section (figure1, 2 and 3). The vascularity and the consistency of the buffalo bull testes showed a difference between the two age groups .They appeared pale in color and very soft in consistency in age group (I) figure(1) and in age group (II) they appear more vascular and firm in consistency, figure(2).

The different testicular parameters:

The different parameter of the buffalo testes in relation to age were shown in Table (1). Analysis of variance between the two age groups indicated a highly significant effect of the age on testicular parameter Table (1).

The testicular weight:

The effect of the age on the testicular weight:

The mean \pm SEM of testicular weight was 51.3 ± 7.59 in age group (I) and 117.5 ± 9.1 in age group (II), Table (1) (Figure 4).

Testicular length:

The effect of the age on the testicular length:

The mean \pm SEM of testicular length was 6.0 ± 0.40 in age group (I) and 8.7 ± 0.26 in age group (II), Table (1), (figure 5).

Testicular width:

The effect of age on testicular width:

The mean \pm SEM of testicular width was 3.9 ± 0.1 in age group (I) and 5.4 ± 0.3 in age group (II), Table (1), (figure 6).

Histological findings:

Microscopic pictures of H&E stained testicular sections from group (I) and group (II) showing wider interstitial space (asterisks) and wider lumen of seminiferous tubules (black arrows) in age group (I) **(A)** when compared with animal group (II) **(B)**. In age group (I) higher magnification showing seminiferous tubules lined with differentiated spermatogenic cells, Sertoli cells and spermatocytes with few spermatids and few desquamated spermatocytes in lumen of some tubules **(C)**. Testicular sections from age group (II) showing seminiferous tubules lined with different stages of developmental spermatogenic cell clusters as Sertoli cells spermatogonia cells, different cell types of spermatocyte, round spermatids and several spermatozoa (black arrows) in lumen of seminiferous tubules **(D)**. In group (I) numbers of interstitial cells of Leydig (yellow arrows) appear fewer **(E)** when compared with group (II) **(F)**. Figure (7).

The effect of age on the diameter of the seminiferous tubule:

The diameter of the seminiferous tubule was varied between (99.90 ± 17.4) and (104.6 ± 15.82) in age group (I) and in age group (II) respectively, Table (2). The change in the seminiferous tubule diameter was significant between the two age groups (figure. 8A).

The effect of age on the thickness of epithelial lining seminiferous tubules:

The thickness of the seminiferous tubule was varied between (26.06 ± 5.51) and (27.64 ± 5.52) in age group (I) and in age group (II) respectively, Table (3) the change in the thickness of the lining epithelium was significance between the two age groups, (figure . 8B).

The effect of age on the number of leydig cells per microscopic field:

The number of leydig cells per microscopic field was varied between (40.14 ± 15.52) and (49.16 ± 27.99) in age group (I) and in age group (II) respectively, Table (4) the change in the number of leydig cells per microscopic field was significance between the two age groups, (figure 8C).

The effect of age on the degree of degeneration:

The degree of degeneration was varied between (6.12 ± 0.79) and (4.62 ± 0.66) in age group (I) and in age group (II) respectively, Table (5) the change in degree of degeneration field was significance between two age groups, (Figure 8D).

Statistical analysis of morphometric quantitative measurements using t test showing significant increase in diameter of seminiferous tubules (A), thickness of epithelial lining (B) and number of Leydig cells (c) in age group (II) when compared with age group (I) ($P < 0.05$), Statistical analysis of degeneration degrees according to 7-stage scale using Mann Whitney test (D) shows significantly lower scale that means higher degeneration in age group (I) when compared with higher scale that means less degeneration in age group (II) ($P < 0.05$). (Figure. 8 A, B, C and D).

Apoptosis in testicular tissue between the two age groups:

The data in table (6) revealed that there was a significant difference in age group (I) between haploid cells with, diploid cells and spermatid, also there was a significant difference between apoptosis in testicular cells and diploid cells and spermatid. In age group (II) the data revealed that there was a significant difference between haploid cells and spermatid. Also there was a significant difference between the apoptosis of the testicular cells and the diploid cells and spermatid in age group (II). The data revealed that there was a significant difference in age group (I) and in age group (II) between haploid cells, spermatid and apoptosis in testicular cells, (figure9).

The electron microscope in testicular tissue between two age groups:

As shown in figure (10), an electron micrograph of testis of age group (I) showed, **A)** More or less normal sertoli cells (S) with indented nucleus (arrow) and normal mitochondria (M), note: focal lytic area surrounded sertoli cell (arrow head). **B)** Normal spermatogonium type B (B) with oval nucleus (N) resting on basal lamina (BL). **C)** Spermatogonium type A (A) with slightly rarified cytoplasm (arrow head) and disrupted mitochondria (arrow), with a decrease electron density of the cell. **D)** Normal primary spermatocyte (sp) with rounded nucleus (N), rough endoplasmic reticulum (RER) and mitochondria (M). **E)** Spermatid giant cell with normal cytoplasm (C), oval nucleus (N) with acrosomal cap (arrow), with normal appearance of Golgi apparatus (circle). **F)** Type A showing fragmented nucleus (astric), Primary spermatocytes (PS) appear with large euchromatic nuclei and many mitochondria. Some of them are disrupted (arrow head). Some cellular debris of degenerated and distorted cell (arrow) in between spermatogenic cells can be seen. While An electron micrograph of testis of age group (II) showing: **A)** Sertoli cell (S) containing a large irregular nucleus (N) with a distorted nucleolus (Nu), spermatogonium type A (A) with rounded nucleus surrounded by lytic area (arrow) resting on the irregular basal lamina (BL), normal spermatocyte with rounded nucleus (sp). **B)** Thick basal lamina (BL) with irregular flat myoid cell (arrow), part of normal sertoli cell containing a large nucleus (N) and more or less normal organelles such as homogenous cytoplasm, mitochondria (M) and RER. **C)** Most probably normal spermatogonium type B (B) with oval regular nucleus (N) resting on the irregular basal lamina (BL). **D)** Primary spermatocyte with chromatin fragmentation in their nucleus (arrow).

E) Normal early round spermatid with rounded nucleus (N), acrosomal cap (arrow), mitochondria (M) and normal RER. **F)** Exfoliation of degenerated secondary spermatocyte (sp) in the lumen **G)** Accumulated heads (arrow) of sperm in between spermatogenic cells. **H)** Longitudinal section of sperms (arrow) in the lumen (L) as shown in figure (11).

The effect of age on level of testosterone in the blood:

The mean concentration ratio \pm SEM of testosterone in the two age groups was shown in table (7), figure (12). The mean level of testosterone in age group (I) was 0.57 ± 0.17 while in age group (II) the mean level Of testosterone was 1.9 ± 0.44 .

Tables:

Table (1): Mean \pm SEM of the whole testicular parameter in two age groups:

Age group	No	TW (gm.)	TL (cm)	TWD (cm)
Group (I)	8	51.3 \pm 7.59	6.0 \pm 0.40	3.9 \pm 0.1
Group (II)	22	117.5 \pm 9.1	8.7 \pm 0.26	5.4 \pm 0.3
Significance		P<0.001	P<0.001	P>0.001

TW: testicular weight, TL: testicular length, TWD: testicular width.

Table (2): Mean \pm SD of the diameter of the seminiferous tubule of the two age groups:

Group	No	Diameter of the seminiferous tubule	Significance
Group (I)	8	99.90 \pm 17.4	P<0.05
Group(II)	22	104.6 \pm 15.82	

Table (3): Mean \pm SD of the thickness of epithelial lining seminiferous tubule of the two age groups:

Group	No	Thickness of epithelial lining seminiferous tubule	Significance
Group (I)	8	26.06 \pm 5.51	P<0.05
Group (II)	22	27.64 \pm 5.52	

Table (4): Mean \pm SD of the number of leydig cell of the two age groups:

Group	No	Number of leydig cell	Significance
Group (I)	8	40.14 \pm 15.52	P<0.05
Group (II)	22	49.16 \pm 27.99	

Table (5): Mean \pm SD of the degree of degeneration of the two age groups:

Group	NO	Degree of degeneration	Significance
Group(I)	8	6.12 \pm 0.79	P <0.05
Group(II)	22	4.62 \pm 0.66	

Table (6): Mean \pm SEM of the number of haploid, diploid, spermatid and apoptosis in testicular tissue between the two age groups:

Parameters	Group(I)	Group(II)	SEM	P-value
Apoptosis	14.95 ^a	7.10 ^b	0.26	<0.0001
Spermatid	47.93 ^b	59.80 ^a	0.27	<0.0001
Diploid	7.60 ^b	16.46 ^b	0.12	<0.0001

Values with different subscripts were significantly different.

Table (7): Mean \pm SEM of testosterone hormone in two age groups:

	No	ng /ml serum	Significance
Group (I)	8	0.57 \pm 0.17	P < 0.05
Group (II)	22	1.9 \pm 0.44	

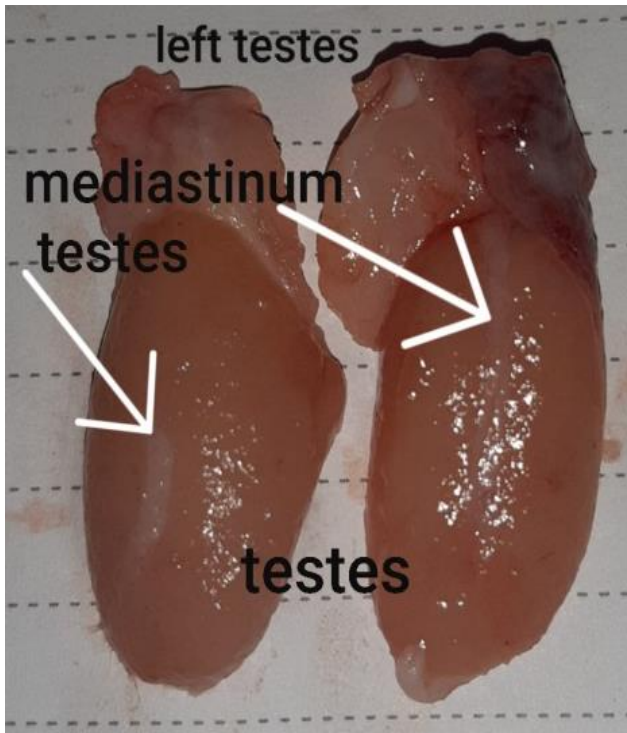


Figure (1): mediastinum testes of buffalo Bull of age group (I).

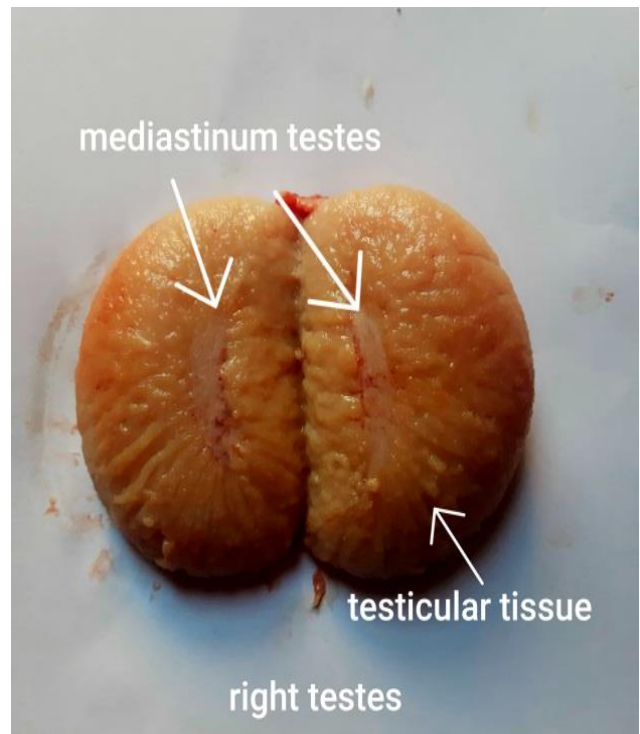


Figure (2): mediastinum testes of buffalo bull of age group (II).

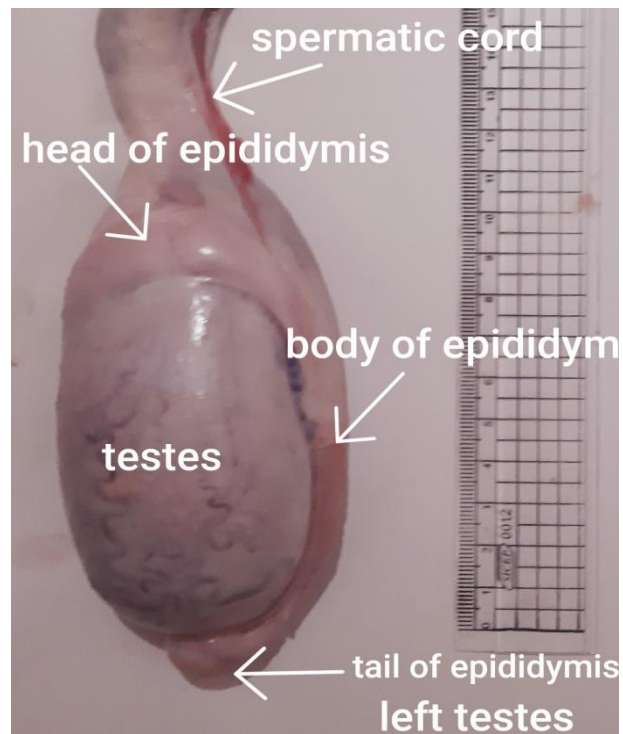


Figure (3): testes of buffalo bull aged 30 month.

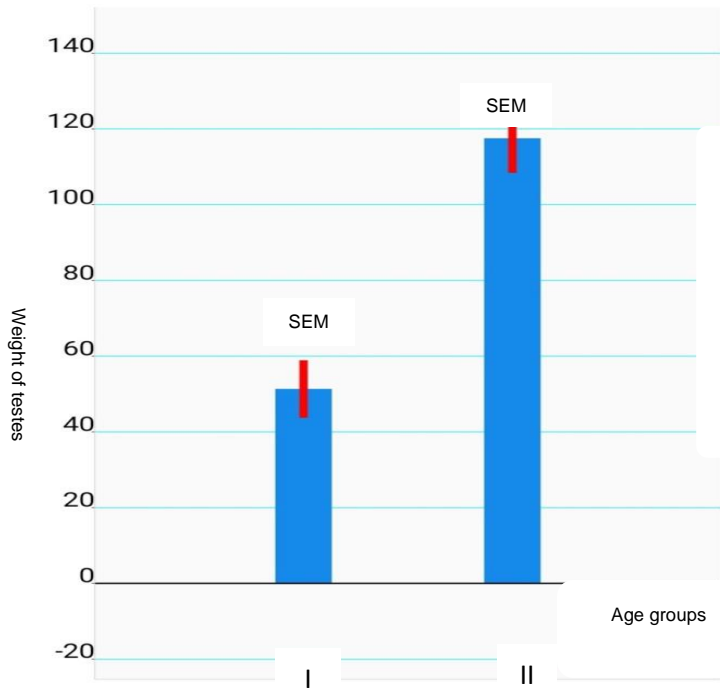


Figure (4): the weight of testes between 2 age groups
(Mean \pm SEM)

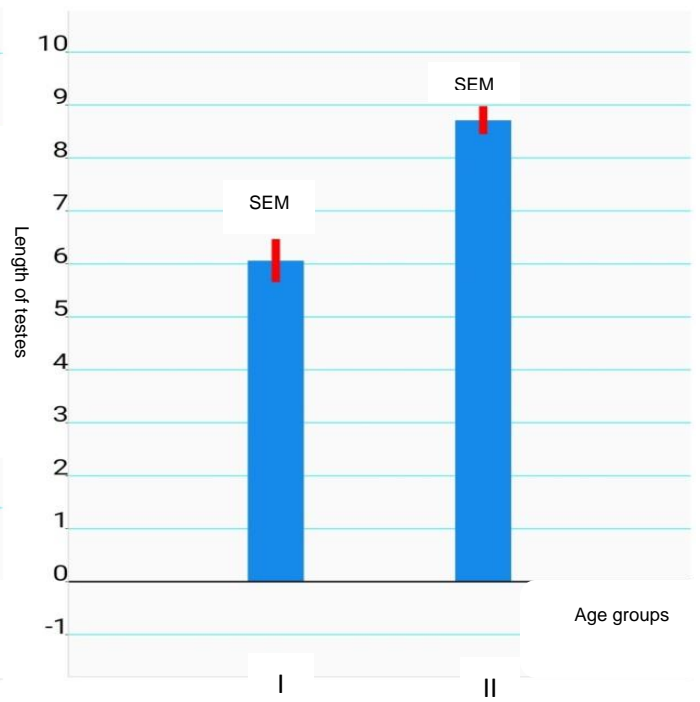


Figure (5): The length of testes between 2 age groups
(Mean \pm SEM)

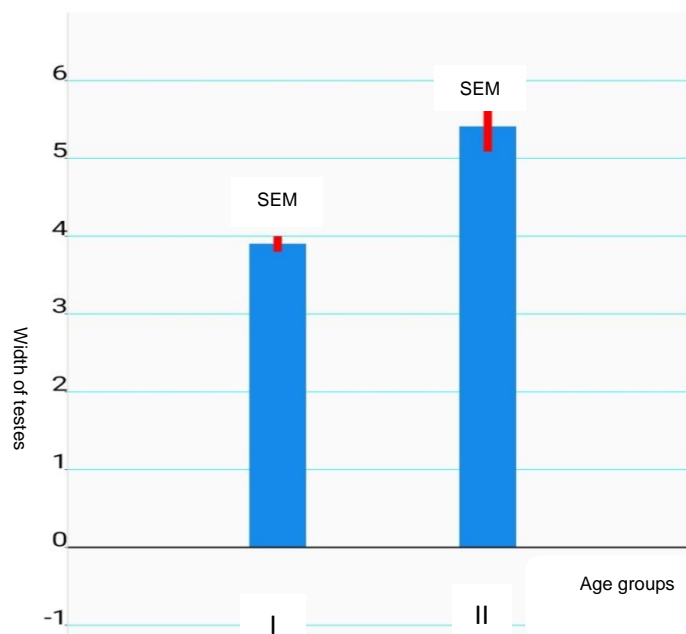


Figure (6): The width of testes between two age groups
(Mean \pm SEM)

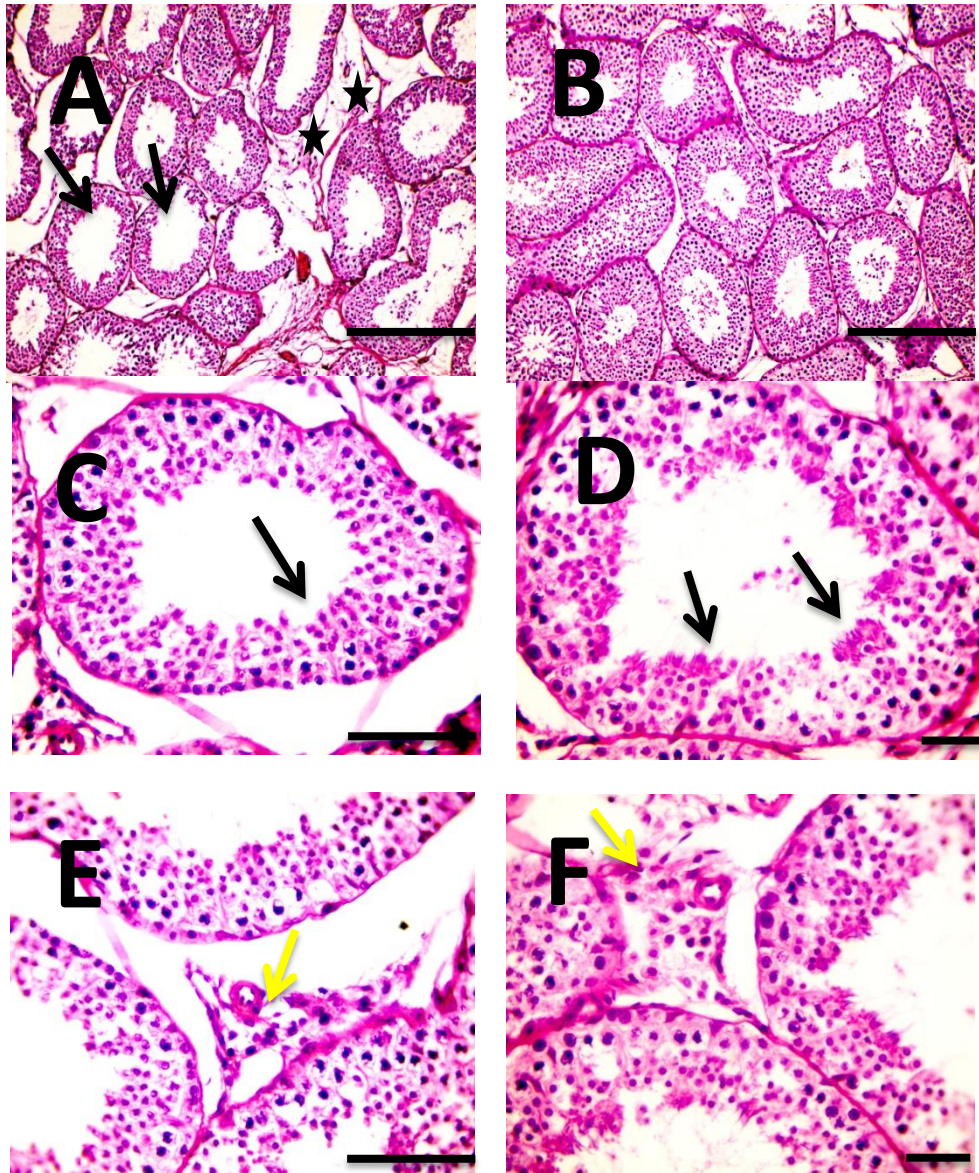


Figure (7): Microscopic pictures of H&E stained testicular sections from group (I) and group (II) animal. X: 100 bar 100 (A&B), X: 400 bar 50 (C-F).

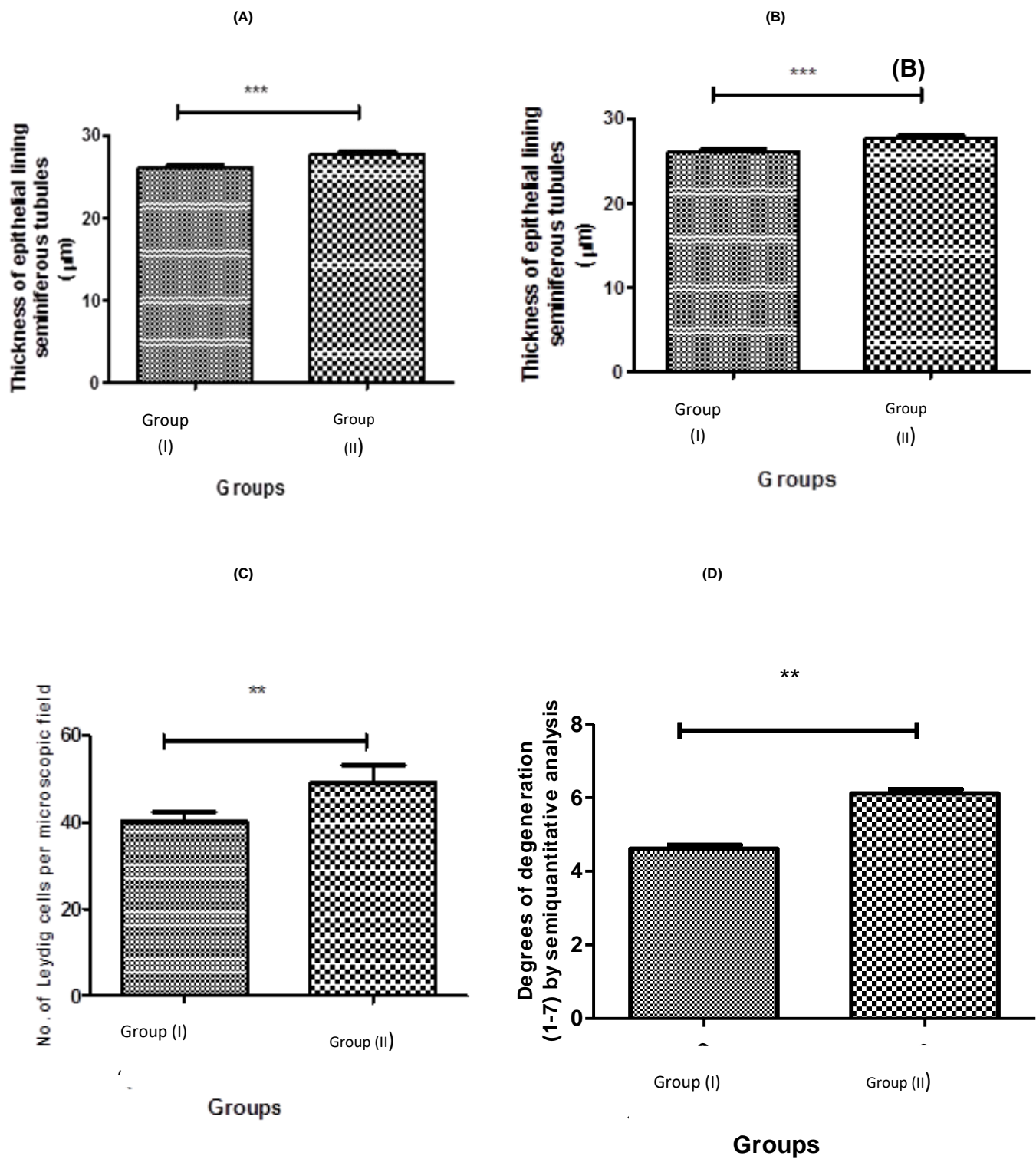
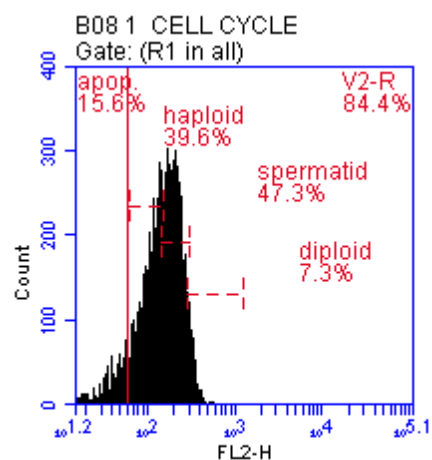
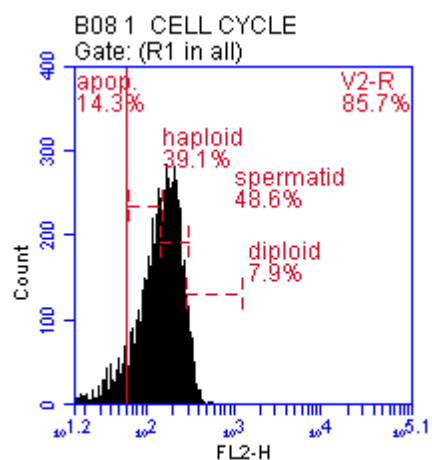
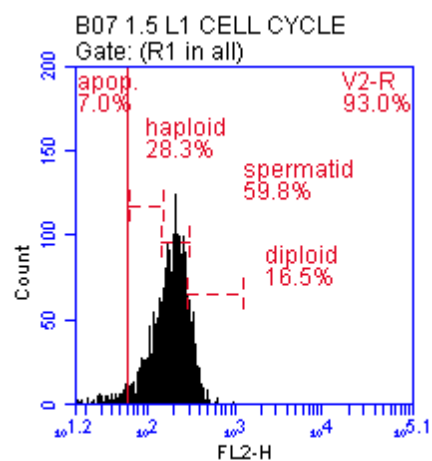
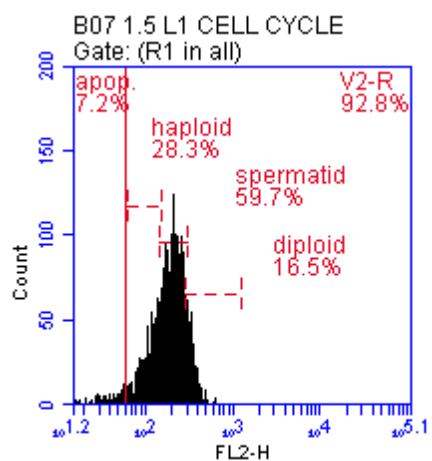


Figure 8 (a, b, c and D): Statistical analysis of morphometric quantitative measurements using t test shown significant increase in diameter of seminiferous tubules (A), thickness of epithelial lining (B), number of Leydig cells (c) in age group (II) when compared with age group (I), and (D) shows higher degeneration in age group (I) when compared with age group (II).

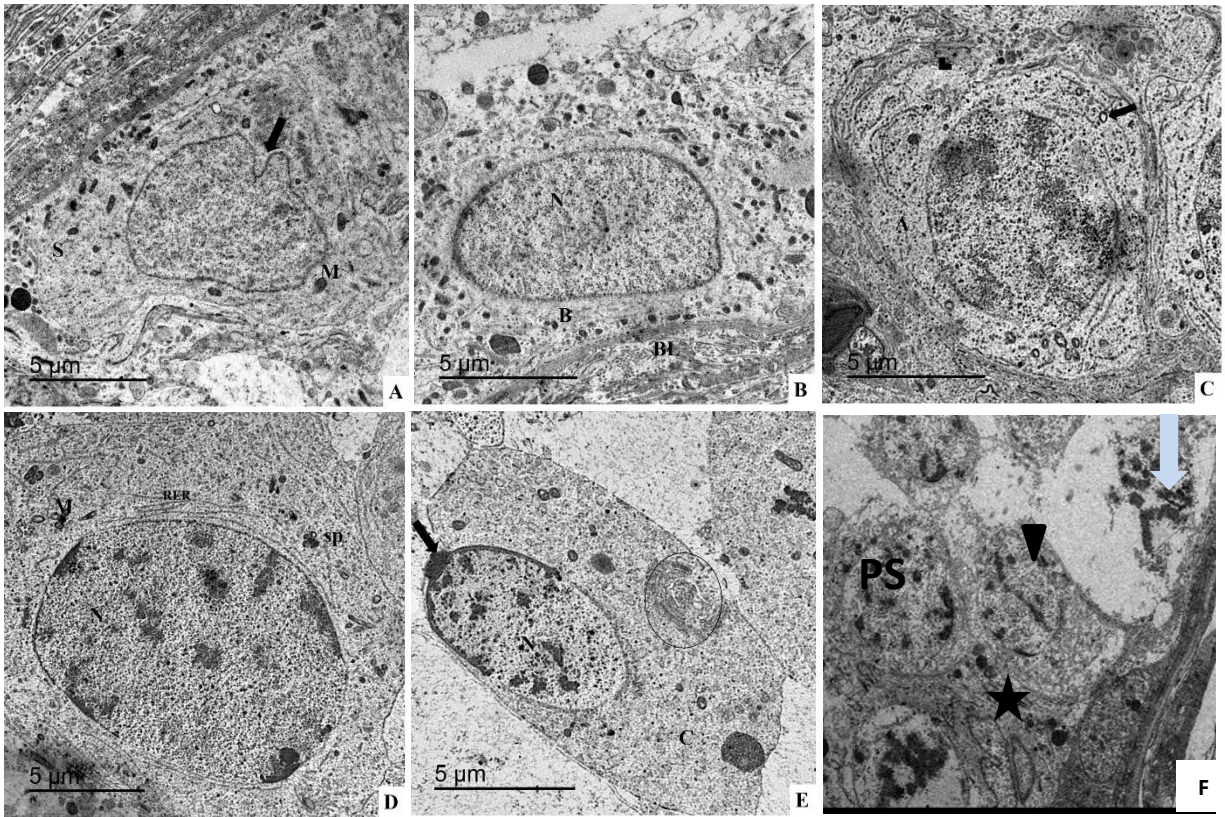


Age group (I)

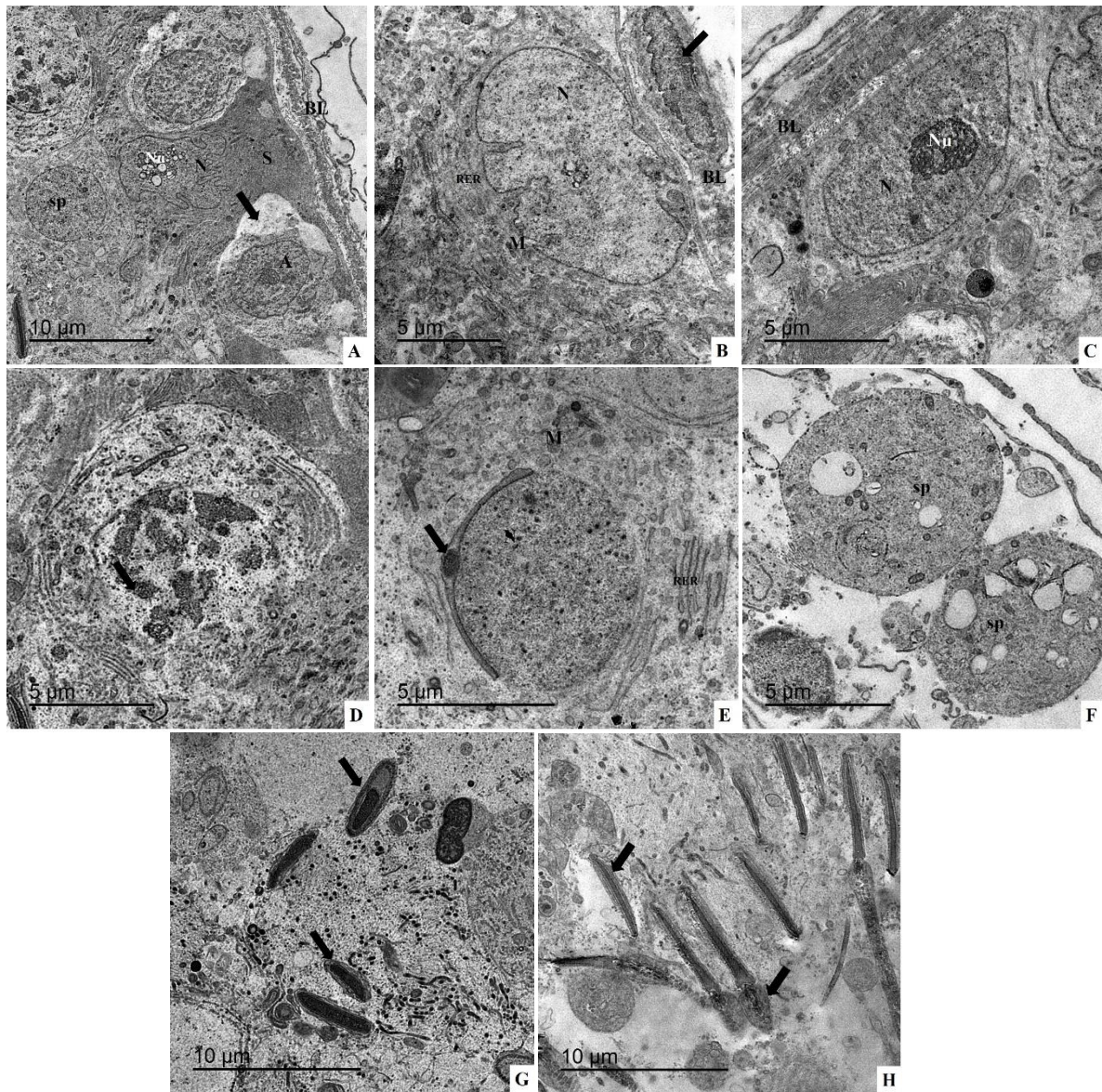


Age group (II)

(Figure 9): A histogram of flow cytometer revealed that there was a significant difference between age group (I) and age group (II).



(Figure 10): An electron micrograph of testis of age group (I) showing the ultrastructure of the different testicular components.



(Figure 11): An electron micrograph of testis of age group (II) showing the Ultrastructure of the different testicular components.

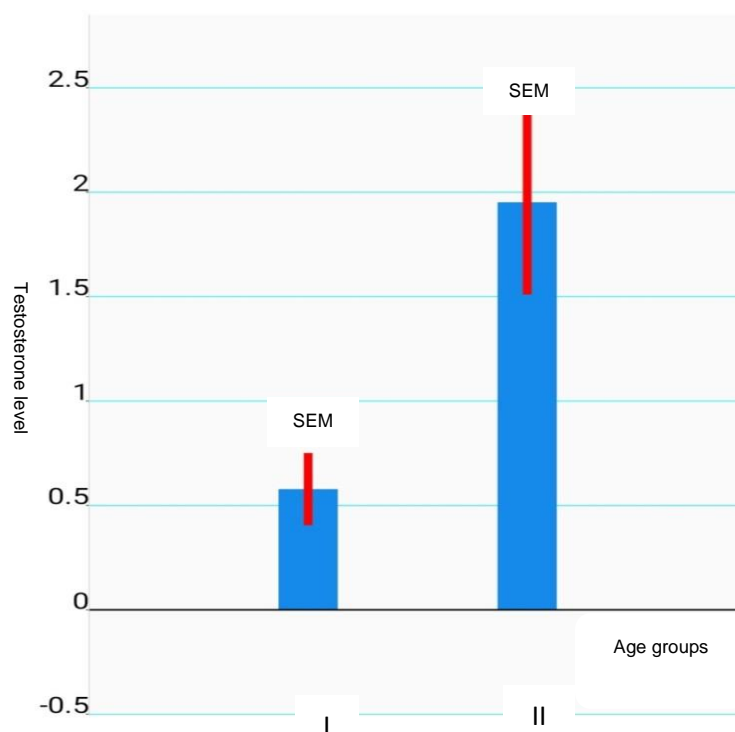


Figure (12): The testosterone level between 2 age groups
(Mean ± SEM)

Discussion

In this study it was found that the testicular biometry (TW, TL and TWD) showed an increase with the advancement of the age. This agreed with **Genedy, et al, (2019)**, **Da Silva Santos, et al, (2013)**, and **Ahmad, et al, (2010)** and disagreed with **Heuer and Bajwa, (1986)** who reported that testicular length was not correlated with age and body weight.

The diameter of seminiferous tubule increased with the advancement of the age and this was in agreement with **Aponte, et al, (2005)**, **Da Luz, (2012)** and **Ahmad, et al, (2010)**.

In this study it was found that the seminiferous epithelium height increased with the advancement of the age and this was in agreement with **Ahmad, et al. (2010)** and **Da Luz et al, (2012)**.

In the current work, the number of leydig cell increased with the advancement of the age which was in agreement with **Rana, and Bilaspur, (2004)**, **Rana, (1996)**. According to **Rana, (1996)** and **Gofur et al, (2008)** the percentage of Leydig cells increased from 3- to 30-month-old animals, but decreased from 30 to

42 months. This could be attributed to increase in seminiferous tubular diameter during this period, resulting in the decrease in interstitial space due to increase connective tissue fibers in the intertubular space, **(MacMillan and Hofs, 1968)**. A further marked increase from 36 to 72 months and older occurred **(Rana, and Bilaspur, 2004)**.

It was founded that the apoptosis, apoptotic DNA fragments and degree of cell degeneration diminished in at age group (II) than in age group (I). So the germ cell production, efficiency and fluctuations were related to age and developmental stages and this was in agreement with **Hingst and Blottner, (1995)** and **Billig, et al, (1995)**. **Aponte, et el, (2005)** they reported that the efficiency of spermatogenic process enhanced after 15 months of age coincided with the onset of puberty in Brahman bulls, presumably with lower apoptosis and reaching of optimal numbers of germ cells provided with accommodations by Sertoli cell. It was suggested that the low levels of testosterone enhanced the apoptotic proces so in age group (I) with its lower testosterone level than age group (II) have higher degrees of apoptosis than age group (II). This was in agreement with **Tapanainen et al, (1993)** and **Tapanainen, and Hsueh, (1994)**, who also reported that androgen is important for differentiation, growth of somatic cells of the testes, beginning and maintenance of spermatogenesis. Testosterone is thought to regulate a number of functions along with the production of the sperm and without sufficient amounts of testosterone, infertility could develop. This is because testosterone helps and supports development of mature sperm **(Finkelstein, et al, 2013)**.

There was no significant variation in the number of diploid cell between the two age groups. This was in agreement with **Aponte, et el, (2005)**, might be owing to a steady, high efficiency value of intermediate spermatogonia: spermatocytes ratio that reached shortly before puberty. The intermediate spermatogonia: spermatocytes ratio indicated the efficiency of the generating spermatocytes from intermediate spermatogonia. It was also founded that the number of spermatids started with low levels and then increased at the age of (18 -36) month and this was in agreement with **Aponte, et el, (2005)** likely as the ratio between spermatocytes and spermatids reached the peak efficiency around 15 month of age (coincided with the onset of puberty in Brahman bulls) which suggested that the losses in spermatids were few **(Aponte, et el,2005)**. Moreover, spermatids found to be more resistant to apoptosis **(Meikrantz, and Schlegel, 1996, Russell and Clermont, 1977 and Huckins and Oakberg, 1978)**. From economical aspect make it sensible that apoptosis of germ cells occurs to maintain the right cell population size and shape at the start of the spermatogenesis **(Blanco-Rodriguez, 1998)**. Programmed cell death, have an essential role in the regulation of activity of gonads as it acts as an antagonist to proliferation, including testicular parenchyma cyclic involution and arrest of spermatogenesis, **(Hikim and Swerdloff, 1999)**.

In this study, it was observed that cellular and molecular features of apoptosis in different testicular components in age group (I) appeared with disrupted mitochondria, a decrease electron density of the cells, abnormal sperms with dilated, rupture and blebbing to its cell membrane. Type A showing fragmented nucleus some cellular debris of degenerated and distorted cells in between spermatogenic cells could be seen. This was in agreement with **Hikim and Swerdloff, (1999), Majno and Joris, (1995), White, (1996) and Jacobson, et al, (1997)**.

The level of testosterone was low in animals < 18 month then increase in animals ≥18 till 36 month (table 1). with advancement of age the testosterone levels increased at 18 month mean (2.5 ng/ml) in agreement

of (Ahmad, N. et al, 1989, Bedair and Thibier, 1979, Gunarajasingam, et al, 1985 and Barreto- Filho, et al, 1996). The period of puberty is associated with quick testicular growth, increased the gonadotropins secretion, testosterone secretion in response to releases of LH and start of spermatogenesis (Hemeida, et al, 1985); During puberty a higher concentration of androgen is required for the beginning of spermatogenesis, (Handelsman, et al, 1999 and O'Donnell, et al, 2017). While disagreed with Sajjad, et al, (2007), Javed, et al, (2000), Gupta, et al, (1984), Rawlings, et al, (1972 and Lacroix, et al, (1977) and Ahmad et al, (1984). This difference might be owing to breed difference and, nutritional factors and seasonal variations (Lunstra, et a, 1978 and Lacroix and Pelletier, 1979).

References

- Abdel-Salam, S., and Fahim, N. (2018):** Classifying and Characterizing Buffalo Farming Systems in the Egyptian Nile Delta Using Cluster Analysis. *Journal of Animal and Poultry Production*, Mansoura University; 9(1): 23-28.
- Ahmad, M., Latif, M., Ahmad, M., Qazi, M. H., Sahir, N., and Arslan, M. (1984):** Age-related changes in body weight, scrotal size and plasma testosterone levels in buffalo bulls (*Bubalus bubalis*); *Theriogenology*, 22(6): 651-656.
- Ahmad, N.; Shahab, M.; Khurshid. S., and Arslan, M. (1989):** Pubertal development in the male buffalo: Longitudinal analysis of body growth, testicular size and serum profiles of testosterone and oestradiol. *Animal Reproduction Science*; 19: (3-4), 161 -170.
- Ahmad, N.; Umair, S.; Shahab, M., and Arslan, M. (2010):** Testicular development and establishment of spermatogenesis in Nili-Ravi buffalo bulls. *Theriogenology*; 73 (1): 20-25.
- Aponte, P. M.; de Rooij, D. G., and Bastidas, P. (2005):** Testicular development in Brahman bulls. *Theriogenology*, 64(6): 1440-1455.
- Aravindan, G. R.; Ravindranath, N.; Gopalakrishnan, K., and Moudgal, N.R. (1990):** DNA flow-cytometric analysis of testicular germ cell populations of the bonnet monkey (*Macaca radiata*) as a function of sexual maturity. *Reproduction*, 89 (2):397-406.
- Barreto- Filho, J. B.; Melo, M. I. V.; Lage, A. P.; Marques Jr, A. P., and Vale Filho, V. R. (1996):** Buffalo (*Bubalus bubalis*) sexual development: endocrinological and testicular histological aspects. II. From 10 to 24 months of age. *Buffalo Bulletin*; 15: 42-44.
- Bashir, S.; Sarma, K.; Suri, S.; Devi, J., and S. Kamil (2012):** Histochemical Studies on the testis of adult Bakerwali Goat (*Capra hircus*). *Indian Journal of Veterinary Anatomy*; 24(1), 50-55.
- Bedair, G. A. M., and Thibier, M. (1979):** Peripheral plasma and androstenedione and testosterone concentrations in bulls before and during puberty. *Reproduction*; 56 (1): 7-10.
- Berndtson, W. E.; Chenoweth, P.J., and Lorton, S.P. (2014):** Sperm production and its harvest, *Animal andrology: theories and applications*. Wallingford: CAB; 11-33.
- Billig, H.; Furuta, I.; Rivier, C.; Tapanainen, J.; Parvinen, M., and Hsueh, A. J. (1995):** Apoptosis in testis germ cells: developmental changes in gonadotropin dependence and localization to selective tubule stages. *Endocrinology*; 136(1): 5-12.
- Blanco-Rodriguez, J. (1998):** A matter of death and life: the significance of germ cell death during spermatogenesis. *International journal of andrology*.21 (5): 236-248.

- Brito, L.F.; Silva, A.E.; Unanian, M.M.; Dode, M.A.; Barbosa, R.T., and Kastelic, J.P. (2004):** Sexual development in early and late maturing *Bos indicus* and *Bos indicus* x *Bos Taurus* crossbred bulls in Brazil. *Theriogenology*; 62 (7): 1198–1217.
- Da Luz, P. A., Andrighetto, C., Santos, P. R., Jorge, A., Constantino, M. V. P., Pereira, F. T., and Neto, A. C. A. (2012):** Daily sperm production and evaluation of morphological reproductive parameters of Murrah buffaloes in an extensive breeding system. *Spermatogenesis*; 2 (2): 88-93.
- Da Silva Santos, P. R., Andrighetto, C., and Jorge, A. M. (2013):** The correlation between age, body weight and testicular parameters in Murrah buffalo bulls raised in Brazil. *Journal of Reproduction and Development*; 59 (1):14-17.
- Eurell, J. A., and Frappier, B. L. (2013):** Dellmann's textbook of veterinary histology. John Wiley and Sons; 233-245.
- Finkelstein, J. S.; Lee, H.; Burnett-Bowie, S. M. J.; Pallais, C.; Yu, E. W., and Benjamin Z. Leder. (2013):** Gonadal steroids and body composition, strength, and sexual function in men. *New England Journal of Medicine*; 369 (11): 1011-1022.
- Genedy, T. M., Hadad, S. S., and Abd El-Razek, E. M. (2019):** Ultrasonographic, Morphometric and Histological Study of Testicular Parameters in Egyptian Water Buffalo Bulls (*Bubalus Bubalis*). *Journal of Advanced Veterinary Research*, 9 (3): 117-122.
- Gofur, M. R.; Khan M. Z. I.; Karim M. R., and Islam, M.N. (2008):** Histomorphology and Histochemistry of Testis of Indigenous Bull (*Bos Indicus*) of Bangladesh Bangl. *Journal of Veterinary Medicine*; 6 (1): 67–74.
- Gridly, M.f. (1960):** Manual of Histological and Special Staining Technique. 2nd edition. McGraw-Hill book company (USA); 28-31, 82-83.
- Gunarajasingam, D. R.; Rajamahendran, B. R.; Downey, R. B., and Lague', P. C. (1985):** Testosterone secretion in young and adult buffalo bull. *Theriogenology*, 24(2): 185-195.
- Gupta, R. C.; Sharma, A.K. and Khurana, N. K. (1984):** Testosterone levels and libido in buffalo bull. 10th Int. Cong. Animal Reproduction Artificial Insemination. University of Illinois (USA), Urbana-Champaign, Chicago; 282.
- Hacker-klom, U.B.; Gohde, W.; Nieschlag, E., and Behre, H.M. (1999):** DNA flow cytometer of human semen. *Human Reproduction*, 14(10): 2506-2512.
- Handelsman, D.J.; Spaliviero, J.A.; Simpson, J.M.; Allan, C.M., and Singh, J. (1999):** Spermatogenesis without gonadotropins maintenance has a lower testosterone threshold than initiation. *Endocrinology*;140 (9): 3938 – 3946.
- Hemeida, N. A.; El-Baghdady, Y. R., and El-Fadaly, M. A. (1985):** Serum profiles of androstenedione, testosterone and LH from birth through puberty in buffalo bull calves. *Reproduction*, 74(2): 311-316.
- Heuer, C., and Bajwa M. A. (1986):** Selection of Nili-Ravia buffalo bull for artificial insemination. *Zuechthygiene*; 21(5): 257-262.
- Hikim, A. S., and Swerdloff, R. S. (1999):** Hormonal and genetic control of germ cell apoptosis in the testis. *Reviews of reproduction*; 4(1): 38-47.
- Hingst, O., and Blottner, S. (1995):** Quantification of apoptosis (programmed cell death) in mammalian testis by DNA-fragmentation ELISA. *Theriogenology*; 44 (3): 313-319.
- Hochereau-de Reviere, M.T.; Courot, M., and Ortavant, R. (1964):** Durée de la spermatogenese chez le taureau étude par autoradiographie testiculaire. In 5th International Congress on Animal Reproduction and Artificial Insemination; (3): 541–546.

Huckins, C., and Oakberg, E. F. (1978): Morphological and quantitative analysis of spermatogonia in mouse testes using whole mounted seminiferous tubules. *Anatomical Record*; 192 (4):519-527.

Jacobson, M. D.; Weil, M., and Raff, M. C. (1997): Programmed cell death in animal development. *Cell*; (88): 347–354.

Javed, M. T.; Khan, A., and Kausar, R. (2000): Effect of age and season on some semen parameters of Nili-Ravi buffalo (*Bubalus bubalis*) bulls. *Vetrinarski Arhiv*; 70 (2): 83- 94.

Karnovsky, M.J. (1965): A formaldehyde -glutaraldehyde fixative of high osmolality for use in electron microscopy. *Journal of Cell Biology*; 27:137-138.

Khishin, S. S. (1951): Studies on the Egyptian buffalo. I. Average age and calving interval. *Empire Journal of Experimental Agriculture*; (19): 185-190.

Lacroix, A., and Pelletier, J. (1979): Short-term variation in plasma LH and testosterone in bull calves from birth to 1 year of age. *Reproduction*; 55 (1): 81- 85.

Lacroix, A.; Gamier, D.H., and Pelletier, J. (1977): temporal fluctuations of plasma LH and testosterone in Charolais bull calves during the first year of life. In *annals de Biologique Animale Biochimie Biophysique*; 17(6): 1013-1019.

Lunstra, D.D.; Ford, J.J., and Echternkamp, S.E. (1978): Puberty in beef bulls: Hormone concentrations, growth, testicular development, sperm production and sexual aggressiveness in bulls of different breeds. *Journal of Animal Science*; 46 (4): 1054-1062.

Macmillan, K. L., and Hafs, H. D. (1968): Gonadal and extra gonadal sperm numbers during reproductive development of Holstein bulls. *Journal of Animal Science*, 27(3): 697-700.

Majno, G., and Joris, I. (1995): Apoptosis, oncosis, and necrosis – an overview of cell death. *American Journal of Pathology*; 146(1):3–15.

Mehta, A., and Paduch, D. A. (2013): The laboratory diagnosis of testosterone deficiency. In *Androgen deficiency and testosterone replacement* (15-31). Humana Press, Totowa, NJ.

Meikrantz, W., and Schlegel, R. (1996): Suppression of apoptosis by dominant mutants of cyclin-dependent protein kinases. *Journal of Biological Chemistry*; (271): 10205-10209.

O'Donnell, L.; Stanton, P., and de Kretser, D. M. (2017): Endocrinology of the male reproductive system and spermatogenesis. In *Endotext* [Internet]. MDText. com, Inc.

Parish, J. A., and Karisch, B. B. (2013): Estimating cattle age using dentition. Publication (Mississippi State University with U.S. Department of Agriculture, Extension Service; (2779): 1-3.

Rana, B. K. (1996): Postnatal development of testis in Murrah buffalo (Doctoral dissertation, Department of Zoology College of Basic Sciences and Humanities, PAU, Ludhiana). 254-258.

Rana, B. K., and Bilaspuri, G.S. (2004): A quantitative study of seminiferous tubular cells in the developing Murrah buffalo testis. *Veterinary Journal*; 167 (1): 95-103.

Rawlings, N.C.; Hafs, H.D., and Swanson, L.V. (1972): Testicular and blood plasma androgens in Holstein bulls from birth through puberty. *Journal of Animal Science*; 34 (3): 435-440.

Reynolds, E.S. (1963): The use of lead citrate at high pH as an electron-opaque stain in electron microscopy. *Journal of Cell Biology*; 17(1): 208-212.

Rommerts, F.F.G. (2004): Testosterone an overview of biosynthesis, transport, metabolism and non-genomic action. IN: Nieschlag, E., Behr, H.M.eds .testosterone action, deficiency, substitution, 3rd edition. Cambridge University press.; 1-38.

- Russell, L. D., and Clermont, Y. (1977):** Degeneration of germ cells in normal, hypophysectomized and hormone treated hypophysectomized rats. *Anatomical Record*. 187(3):347-356.
- Ruxton, G. D. (2006):** The unequal variance t-test is an underused alternative to Student's t-test and the Mann–Whitney U test. *Behavioral Ecology*; 17(4): 688-690.
- Sajjad, M.; Ali, S.; Ullah, N.; Anwar, M.; Akhter, S., and Andrabi, S. M. H. (2007):** Blood serum testosterone level and its relationship with scrotal circumference and semen characteristics in Nili-Ravi buffalo bulls. *Pakistan Veterinary Journal*; 27(2): 63-66.
- Tapanainen, J. S., and Hsueh, A. J. (1994):** Hormonal Control of Apoptotic Cell Death in the Testis. In *Function of Somatic Cells in the Testis* (pp. 265-271). Springer, New York, NY.
- Tapanainen, J.S.; Tilly, J.L.; Vihko, K.K., and Hsueh, A.W.J. (1993):** Hormonal control of apoptotic cell death in the testis: gonadotropins and androgens as testicular cell survival factors. *Molecular Endocrinology*; 7 (5): 643-650.
- United State Department of Agriculture (1898):** Determination of age by teeth in domestic animals. In *Yearbook of the United State Department of Agriculture*: Washington, D.C., 667.
- Vindelov, L.L. (1977):** Flow microfluorometric analysis of nuclear DNA in cells from solid tumors and cell suspensions. A new method for rapid isolation and staining of nuclei. *Virchows Arch B*; 24 (1): 227- 242.
- White, E. (1996):** Life, death, and the pursuit of apoptosis. *Genes and Development*. 10 (1): 1–15.